

Utilization of Lead Citrate on the Peripheral Nervous System in Rat (An Experimental and Histological Study)

*Ayad Hameed Ibraheem, **Sabah Shahab AL-Tekrity

*Department of anatomy, Histology and Embryology,

**Department of physiology, biochemistry and pharmacology,
College of Veterinary Medicine, University of Tikrit, Tikrit, Iraq.

Received 27/10/2009 Accepted 10/1/2010

Abstract

Sixty adult rat (Sprague-Dawely) were used in this study, Fourty animals were administrated of lead citrate solution with phosphate buffer saline orally in a dose of 250 mg/kg for thirty days. Animals were divided into four groups. Group A survived for 30 days. Group B for 60 days. Group C for 90 days and Group D 120 days. Twenty animals were administrated phosphate buffer saline for 30 days and classified into four 4 groups and survived for 30, 60, 90 and 120 days after the last dose. At the end of each period the animals were scarified and segments of the peripheral nerve (Sciatic nerve) were removed and fixed in osmic acid 1% , then processed in graded glycerin 50% , pure glycerin for obtaining teased nerve fibers . Specimens for microscopic examination were done by application of the histological technique for obtaining transverse and longitudinal sections of the 6um thickness. The results of the present study demonstrated that the peripheral nerve fibers were affected after the 30, and 60 days mostly reflected by the presence of the wallerian degeneration (destruction of the myelin sheath and axon) of the most nerve fibers and at the period of 90 days after the last dose was indicated a regeneration of the most nerve fibers , but still there certain percentage of the degenerated nerve fibers and irregular outlines of its myelin sheath . After 120 days, Remyelination of most nerve fibers were detected associated with short internodes in between other intact nodes of Ranvier .

تأثير استخدام سترات الرصاص على الجهاز العصبي المحيطي في الجرذ (دراسة تجريبية نسيجية)

أياد حميد إبراهيم صباح شهاب التكريتي

المستخلص

ستون جرذ بالغ تم استخدامها في هذه الدراسة. أربعون من هذه الحيوانات تم تجريبها سترات الرصاص المذابة في محلول منظم الفوسفات عن طريق الفم بجرعة 250 ملغ/كغم لمدة 30 يوم متواصلة. الحيوانات تم تقسيمها بالتساوي إلى أربع مجاميع. مجموعة (أ) عاشت لمدة 30 يوم. مجموعة (ب) استمرت لمدة 60 يوم. مجموعة (ج) لمدة 90 يوم ومجموعة (د) استمرت 120 يوم. في نهاية كل فترة تم قتلها بجرعة عالية من الكلوروفورم في صندوق زجاجي مغلق , أخذ أجزاء من العصب الطرفي (العصب الوركي) وثبت في حامض الاوزميك 1% وتم تمريره في محلول 50% كلسيرين ثم كلسيرين نقي وذلك للحصول على ألياف عصبية منفردة. العينات الخاصة بالفحص المجهرى تم إعدادها من خلال التقنية النسيجية للحصول على مقاطع عرضية وطولية بسمك 6

مايكروميتر. أظهرت نتائج الدراسة الحالية بأن الألياف العصبية الطرفية قد تعرضت للآذى بعد 30 يوم و 60 يوم حيث ظهر تنكس للأغمد النخاعينية لمعظم تلك الألياف , وفي مرحلة 90 يوم تبين حصول إعادة التنام معظم الألياف العصبية , لكن هناك نسبة معينة من الألياف المتكسمة مع وجود عدم انتظام الشكل الخارجي للغمد النخاعيني. بعد 120 يوم , وتبين ان هناك إعادة تكوين الغمد النخاعيني لمعظم الألياف وجود ألياف عصبية قصيرة العقد بين عقد رانفير السليمة, إلى جانب ماسبق فقد تم تقسيم عشرون اخر من الحيوانات الى اربعة مجاميع متساوية جرعت محلول الفوسفات .

Introduction

Chronic lead neuropathy and nephropathy remains a cause of morbidity and mortality in the large areas of the world and in the other parts of the industrial world (1). The mechanisms responsible for the neurotoxic effects of lead remain poorly understood (2). Atsdr(3) mentioned that there is some evidence that exposure to lead may affect adults reflected by postural balance and peripheral nerve function, also slowed nerve conduction and forearm extensor weakness (wrist drop), recently signs of lead intoxication ,are more classic signs in workers chronically exposed to high lead levels . In children, acute exposure to very high levels of lead may produce encephalopathy and their accompanying signs of ataxia, coma, convulsion and even death, otherwise its effect in the peripheral nerves associated with the disrupt balance and impair peripheral nerve function(4).Kordas, et al(5) demonstrated that ingestion of the most common route of exposure to lead for children,. The defect in the blood brain or blood nerve barrier is the main cause for increase the risk of leads entry into the nervous system which can result in prolonged or permanent neurobehavioral disorders (6).Lead toxicity can affect every organ in the body, The nervous system is the most sensitive target to lead exposure (7). And the route that most commonly leads to illness.

Materials and Methods

Sixty adult rats (Sprague-Dawely) were used in the present study. Fourty animals were given lead citrate dissolved in the phosphate buffer saline orally in a dose of

250mg/kg. The lead citrate was administrated orally for 30 days successfully. The animals were equally classified into (4) groups as follows:-

Group A Survived for 30 days after the last dose

Group B Survived for 60 days after the last dose

Group C Survived for 90 days after the last dose

Group D Survived for 120 days after the last dose

Twenty rat were administrated phosphate buffer saline orally 2 ml daily for 30 days and equally classified into 4 groups survived for 30, 60, 90, and 120 days after the last dose of saline . The animals at the end of each survival period were sacrificed and a segments of the sciatic nerve were obtained and processed in aldehyde fixative , then fixed in osmic acid 1% , followed by washing in phosphate buffer saline (PBS). Specimens were placed in 50% glycerin for softening for 24 hour; the specimens were transferred into pure glycerin for 48 hours (8). Teasing of nerve segments were carried out under dissecting microscope to identify the effect of the lead citrate on the nerve. The histological technique was made by placing a segment of the sciatic nerve in the graded alcohol series for dehydration. The tissues then cleared in xylene and then placed in the paraffin wax for infiltration. Transverse and longitudinal sections (6) um thicknesses were cut using the

microtome and stained with Haematoxylin and Eosin (9). The present study was designed to demonstrate the effect of lead citrate on the peripheral nervous system of the rats after administration the lead orally for successive (30) days , followed by demonstration the regeneration of (P.NS) after different survival periods.

Results

Group A: - This group was demonstrated the degeneration of myelin sheath and axon of most nerve fibers (WD) and the presence of fragmented myelin and macrophages in between the others nerve fibers (Demyelination). Certain nerve fibers were associated with the presence of irregular outlines, particularly the myelin sheath (Fig.1).

Group B:- In this group, the degenerative changes nerve fibers was reflected by swelling of individual nerve fibers and irregular outline, also there was breaking down of individual nerve fibers (Fig.2).

Group 3:- There was individual nerve fibers which were affected as degenerated fibers, but others were either not affected or remyelinated after the period of degenerative process, so the effect of degeneration in this period was less. (Fig.3).

Group 4:- In this period , the degenerative changes were rare, mostly were appeared normal , however the individual nerve fibers were still affected but was not significant in comparison with the former periods of 30, 60 and 90 days post survival periods. The nerve fibers appeared in different diameter and this feature was the dominant of the whole peripheral nerve fibers (Fig.4). The control animal groups of whole survived periods appeared normal in its texture and outline ,and were smooth and no changes in the axons or myelin sheath (Fig.5&6).

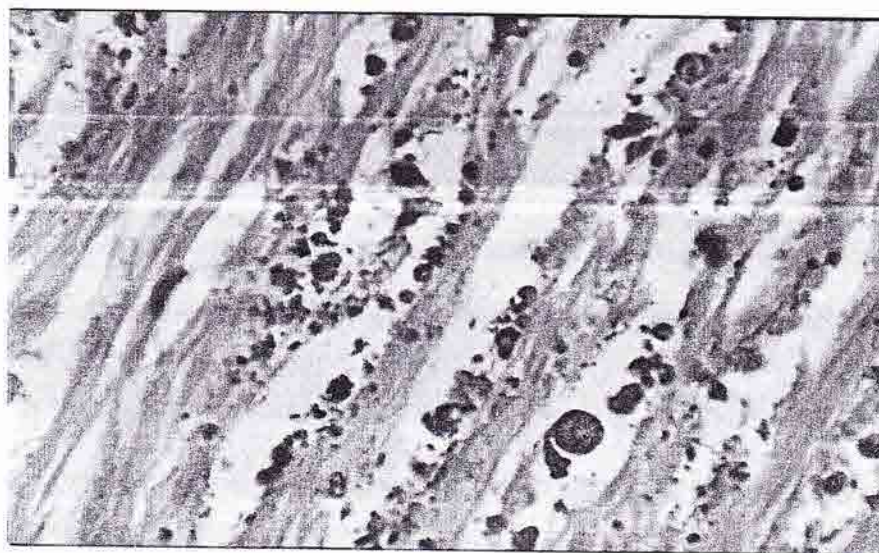


Fig. (1):- Longitudinal section fragmented axons and myelin Sheath associated with the macrophages of the sciatic nerve (osmic acid X 500).

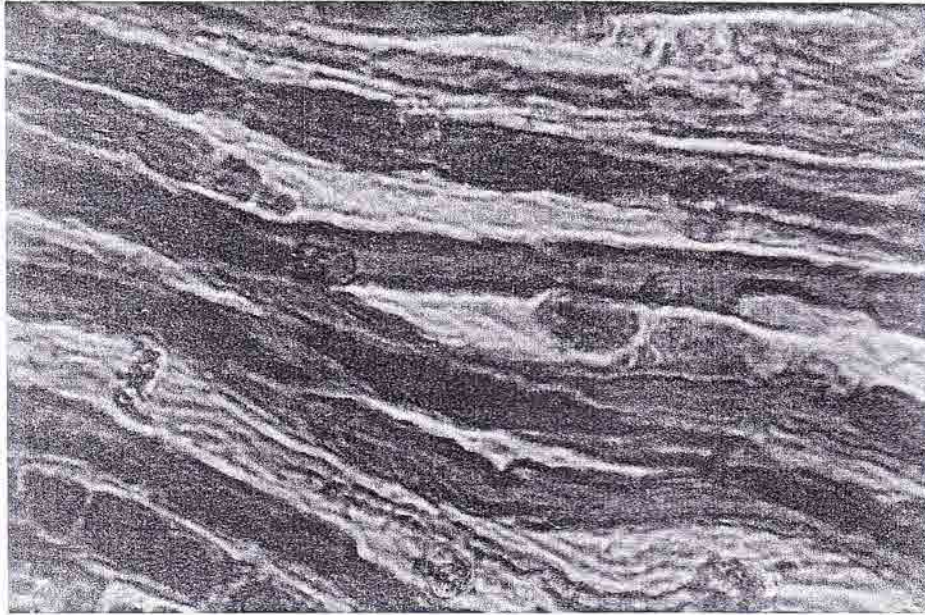


Fig. (2):- Teased nerve fibers demonstrating the presence of the breaking down nerve fibers And irregular outlines of the these fibers (osmic acid X 500).

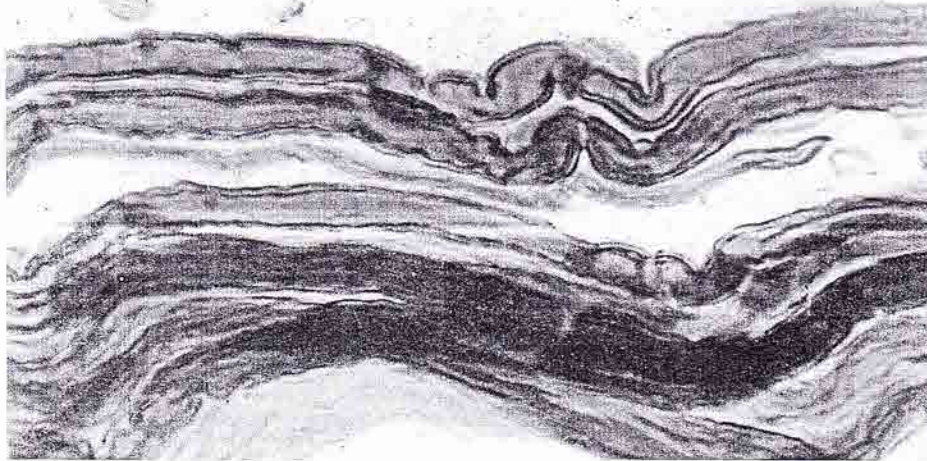


Fig. (3):- Teased nerve fibers associated with the absence of the wallerian degeneration, with some irregular outlines of most nerve fibers and deformity in certain Nodes of Ranvier (Osmic Acid stain1%). X 500.

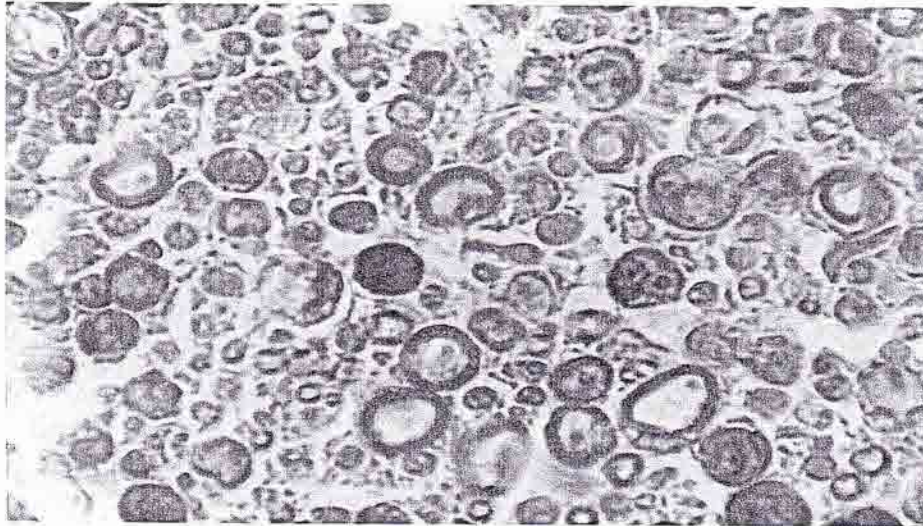


Fig. (4):- cross section of sciatic nerve demonstrating variable diameters of the nerve fibers formed by axons covered by myelin sheath, individual degenerated nerve fibers (Osmic Acid 1%). X500

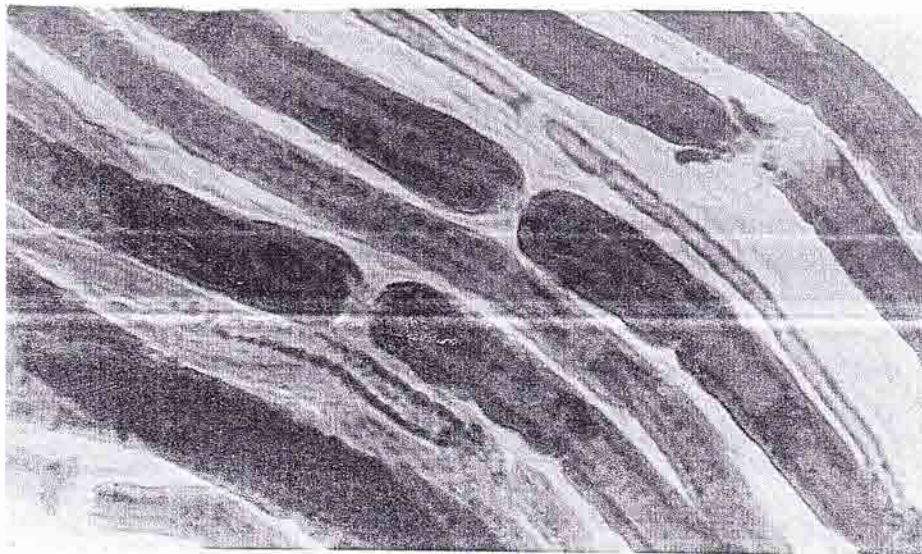


Fig. (5):-Contol group of the rats showing the smooth outlines of the nerve fibers associated regular contour of the Nodes of Ranvier. (Teased nerve fibers, Osmic Acid 1%). X500.

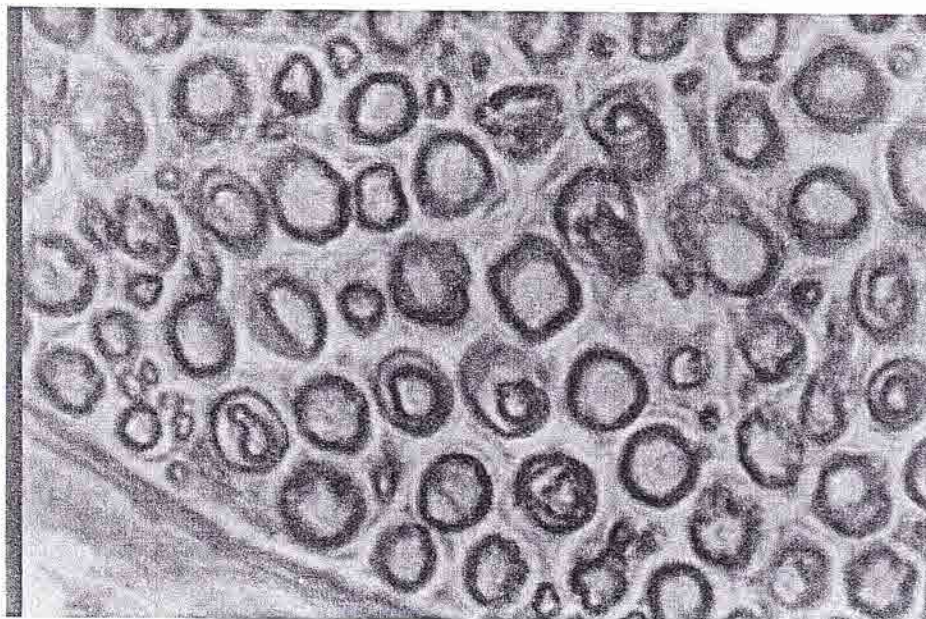


Fig (6):- Cross section of sciatic nerve of the control group of the rats demonstrating presence of the axons surrounded by the myelin sheath (Osmic Acid 1%). X 500.

Discussion

The toxicological data about the lead demonstrated that LD50 of the oral dose in the rat was 466mg/kg (trihydrate form)(10). So this dose was less than that induced in the present study which was 250mg/kg, however the effect was prominent in the lesser dose of the present study on the peripheral nervous system and this effect also recorded by (3) who mentioned that lead exposure may affect adults via postural balance and peripheral nerve function. Otto (11) stated that although the lead toxicity can affect every organ & system but the nervous system is the most sensitive target of lead exposure. In the present study the time for giving the lead citrate for animals was continued for 30 successive days which are corresponding to the concept of Griffin (12) who mentioned that the half-life of lead in adult human blood has been estimated to be from 28-36 days. In the present study demonstrated that myelin and axon destruction (Wallerian degeneration) were evident after 30 days post administration of the lead citrate, these are corresponding to (13) which induced fragmentation of the myelin and axons of the

peripheral nerves by administration of the lead acetate orally in the experimental rats after 15 and 30 days post administration. After 90 days of induction of lead neuropathy, recovery of the nerves was evident, reflected by increase the intermodal length of certain nerve fibers and improvement of the outlines of the nerve fibers, also decrease in the fragmentation of the associated with the individual short internodes, which reflect reducing in the functional activity of the peripheral nerves and these findings are confirm the hypothesis of (14) who stated that the regeneration of the injured nerve is associated with the formation of short internodes as well destructed fibers in between the other nerve fibers, these are associated with more improvement at the period of 120 day although this period as abnormal nodes of Ranvier which are considered as the regenerative process of the injured nerve, which usually associated with abnormal function of the involved nerves.

References

- 1- Craswell, P.W. Chronic lead nephropathy. 1987. *Ann. Rev.Med.*38: 169-173.
- 2- Singh,A.K.Age-dependent neurotoxicity in rats chronically exposed to low levels of lead, calcium hemostasis in Central nervous system. *Neurotoxicol.* 4. 417-427.
- 3- Atsdr, Lead toxicity. 2005. J. Trace elements in medicine and Biology.
- 4- Atsdr, Lead toxicity. 2008. Case studies in environmental Medicine. Pp 31-71.
- 5- Kordas, K., Lopez,P and Rosado,L . Blood lead, Anemia and short stature are independently associated with cognitive performance in mexico school children .*J.Nutr.* 2004. 134, 363-37.
- 6- Seitz, R.J, Reiners,K and Toyka,V . The blood-nerve barrier in wallerian degeneration. 1989.*Mus. Ner.* 12: 627-35.
- 7- Murata, K., Araki, S and Landrigan, P.L. The effect of chronic toxicity by lead salts on the central, peripheral and autonomic nervous system in the human. *Environ. Res.* 1993. 61. 323-336.
- 8- Karnovsky, M.J. Formal dehyde-Gluterldehyde fixation of high osomlarity for use in electron microscopy. 1965. *J.Cell.Biol.* 27; 137-138.
- 9- Luna, L.G. Manual of histologic staining methods. The armed forces institute of pathology.3rd ed. Mcgraw Hill Book Company. N.Y. 1968.
- 10- El-Gazzar, R.M., Finelli,V.N., Boiano,J., and Petering, H.G. Influence of dietary zink on lead toxicity in rats .*Toxicol.Lett.*1978. 1, 227-234.
- 11- Otto,D.A., Fox, D. Auditory and visual dysfunction following lead exposure. 1993.*Neurotoxicolo.* 14: (2-4): 191-207.
- 12-Griffin, j. w., George, R., lobato, c.,Tyor, W.R. (1992):Macrophage responses and myelin clearance during wallerian degeneration: Relevance to immune-mediated demyelination j .*Neuroimmunol.* 40: 153-166.
- 13-Al-Tikrity, A.H. Experimental induction of lead neuropathy in the adult rat. 1999. *Veterinar.* 9 (1). Pp118-124.
- 14-Hildebrand,C., Bowe,C and Remahl, N. Myelination and myelin sheath remodeling in normal and pathological peripheral nervous system. 1994. *Neurobiol.* 43: 85-141.