

## Experimental induction of delay union in femur bone fracture and its effect on the adjacent skeletal muscles

Ban Ismael Seddeek

College of dentistry, University of Tikrit, Tikrit, Iraq

Received 18 /12 /2008 accepted 2 /6 /2009

### Abstract

Bone fracture and its healing process have been extensively investigated for many years. in this study bone delayed union and its effect on the adjacent muscle was investigated. Ten local breed adult rabbits of both sexes weighing 1200-1500 g were used in the experiment. All animals were undergoing surgical operations to induce a transverse closed fracture in the midshaft of the femur, All animals were survived for five months' and then killed using high dose inhalation of chloroform inside glass box. The surgical procedures were made under (general anesthesia) of 50mg/kg Ketamin hydrochloride. A 5 cm longitudinal incision was made on the lateral side of the right thigh. the fractured bone were fixed using intramedullary fixation). Approximate the two fragments and a gap of about 2.5-3 mm length was left to prevent normal bone union. The length and weight of each muscle were measured. Comparison between right and left side for both weight and length was made. A specimen from the muscles of anterior group of thigh (i.e. Rectus femoris), posterior group of thigh (i.e. biceps femoris), anterior group of leg (i.e.tibialis anterior), and posterior group of leg (i.e. soleus) for both right and left was taken. Sample also from fracture site was taken. Staining of sections using Haematoxylin and eosin.the result revealed a significant decrease in muscle fibers weight and diameters. It was concluded that the delay in bone healing reflected on recovery of the weight and diameter of adjacent skeletal muscle fibers.

التحفيظ التجريبي لبطء التئام كسر عظم الفخذ وتأثيره على العضلات الهيكلية المجاورة في الارانب

بان إسماعيل صديق

### المستخلص

كسر عظم الفخذ وعملية التئامه بحثت بصورة مكثفة لعدة سنوات و في هذه الدراسة بحث تأخر التئام العظم وتأثيره على العضلات المجاورة. عشرة أرانب محلية من كلا الجنسين يتراوح وزنها ما بين 1200-1500 غم أستعملت في هذه التجربة. كل الحيوانات خضعت لعملية جراحية لاحداث كسر مستعرض مغلق في منتصف عظم الفخذ. كل الحيوانات بقيت على قيد الحياة لمدة خمسة اشهر وبعدها قتلت بأستعمال جرعة عالية استنشاقية من الكلوروفورم داخل صندوق زجاجي. اجريت الخطوات الجراحية تحت تأثير المخدر العام من 50 ملغم/كغم كيتامين هايدروكلورايد. وثبت العظم المكسور باستعمال مثبت داخل القناة. قرب جزئي العظم المكسور وتركت فسحة بطول 2.5-3 ملم لمنع الالتئام الطبيعي. قيس طول ووزن كل عضلة وقطر الليف العضلي وعملت مقارنة بين جهتي اليمين واليسار بالنسبة للطول والوزن والقطر. اخذت عينة من العضلات الامامية للفخذ (rectus femoris) والمجموعة الخلفية للفخذ (biceps femoris) والمجموعة الامامية للساق (tibialis) والمجموعة الخلفية للساق (soleus) من كلتا الجهتين اليمنى واليسرى واخذت عينة من العظم المكسور ايضا. تم صبغ المقاطع باستعمال صبغة الهيماتوكسلين والايوسين. بينت النتائج نقصان معنوي في وزن وقطر الالياف العضلية. استنتج من ذلك ان التأخر في التئام العظم ينعكس على وزن وقطر الالياف العضلية الهيكلية القريبة.

## Introduction

Bone fracture defined as a mechanically produced disruption in the continuity of the bone, such defects vary from a simple linear break, to an explosive comminution(1). Fracture healing is a process of restoring the structural and biological properties of injured bone(2). Despite the growing knowledge of the mechanisms of fracture healing, delay unions and non-unions remain a substantial clinical problem(3). Several studies were made to determine the effect of bone fracture on muscle(4),(5). The present study was designated to show the anatomical and histological effects of delay union in bone fracture on the adjacent skeletal muscles.

### *Review of literature:*

Weaver (6)classified the fracture according to, position of the bone ends after fracture, completeness of break, the orientation of the fracture to the long axis and penetration of the skin. The major diaphyseal fracture models are mouse, rat, rabbit, dog, sheep, goat, cat and calf. But the most commonly used are rat, rabbit, dog, and sheep as recorded by Koivukangas(7).

### *Repair of fracture:*

The goal of any method of fracture repair should be the early return to function of the organ with minimum post operative morbidity(8). Einhorn(9) said that the process of fracture healing can occur in two ways, direct or primary bone healing (without callus formation), indirect or secondary bone healing with a callus precursor stage. Newton(10) found that primary bone formation occurs in rigid fixation in areas in which small gaps are present. Secondary healing of bone as described by Green baum and Kanat(11) involved the classical stages of fracture healing i.e. impaction, inflammation, primary soft callus formation, callus mineralization and callus remodeling. Jagmin(12)

summarized the fracture healing process and its duration in human as follows:1-haematoma formation (1 to 3 days)/2-fibrocartilage formation (3 days to 2 weeks)/3- Callus formation (2 to 6 weeks)/4- Ossification (3 weeks to 6 months)/5- Remodeling (6 months to 1 year) Condition influencing fracture healing: Cruess and Dumont(13) classified the condition influencing the fracture healing into local & systemic 1/Local factor:a-degree of local trauma/b-degree of bone loss/c-the types of bone involved/d-degree of fracture immobilization./e-degree of fracture gap(14),(3)./f-presence of muscle./g-infection./h-local/malignancy./i-radiation necrosis of bone. 2- systemic factor./a-age(15),(16)./b-hormones.ruess&Dumont (13)and systemic disease like diabetes(2,17). 3-Vitamin:D(18) And E(19).

### *Relationship between bone and muscle:*

In a study of Heinonen et al on prepubertal and early pubertal girls they let them to jump for a period of time and then muscle cross section area and bone cortical area was measured with magnetic resonance. They concluded that muscle area was most highly associated with bone cortical area.

## Materials and methods

1-Ten adult Rabbits of local breed of both sexes weighing 1200-1500 g were used in the experiment. All were allowed free access to food and water before the experiment, and housed in steel cages at room temperature (20-25) °C. All animals were undergoing surgical operations to induce a transverse closed fracture in the midshaft of the femur, All animals were survived for five months' and then killed using high dose inhalation of chloroform inside glass box..

were survived for five months' and then killed using high dose inhalation of chloroform inside glass box..

**2- Operation procedures:** The surgical procedures were made under intramuscular anesthesia (general anesthesia) of 50mg/kg Ketamin hydrochloride on left thigh (21). The site of operation was prepared by skin shaving and local antiseptis application at the lateral side of right thigh region. A 5 cm longitudinal incision was made on the lateral side of the right thigh in an imaginary line that connected between greater trochanter and patella, and then incision was made in fascia lata to expose the underlying muscles. Vastus lateralis muscle separated anteriorly and biceps femoris and caudofemoralis muscles posteriorly using blunt instrument to expose the femoral shaft (22). Muscles then separated from the bone only at the middle third region of the femur shaft by passing the curved artery forceps under the bone (23), Induction of fracture was made using a wire saw (22). The two fragments of fractured bone were fixed using intramedullary fixation [3 stainless steel wire of 1mm in diameter and 5-5.5 cm in length] (7). Approximate the two fragments and a gap of about 2.5-3 mm length was left to prevent normal bone union. Topical antibiotic powder (procaine penicillin) was placed at the fracture side to prevent infection (22, 24). The muscles returned to their normal position by interrupted suture using (chromic catgut) size 3.0 and Fascia lata sutured by continuous suture using the same suture of muscles. Then the skin sutured by interrupted suture using (black silk) size 3.0. Packed the area using plaster, after 8-10 days the suture was removed.

**3- Dissection of animals:** All animals were survived for its end period and then killed .The animals were dissected, bicepsfemoris and

rectusfemoris muscles from the thigh region for both right and left sides. These muscles were removed from its origin and insertion for both right side (experimental) and the left side (control). The length and weight of each muscle were measured using vernier and electronic balance (Mettler AE 200). Comparison between right and left side for both weight and length was made. A specimen from the muscles of anterior group of thigh (i.e. Rectus femoris), posterior group of thigh (i.e. biceps femoris), anterior group of leg (i.e.tibialis anterior), and posterior group of leg (i.e. soleus) for both right and left was taken and immersed in 10% formalin for 24h for fixation and tissue processing purposes.

**4- Preparation of tissue for light microscopy:**After fixation, each muscles sample were cut with a blade at midbelly perpendicular to the long axis of muscle in to small piece (5mm) in length with whole width of muscle (25).

The specimens washed in running tap water, dehydrated through graded ethyl alcohol, ½ hour for each, and cleared by xylol. Then, embedded in melted paraffin inside paraffin bath at 64 °C for 2 hours and blocked in paraffin wax. Muscles were sectioned at 5 µm thickness using Cambridge rotary microtome. Staining of sections using Haematoxylin and eosin (100).

#### **Statistical analysis:**

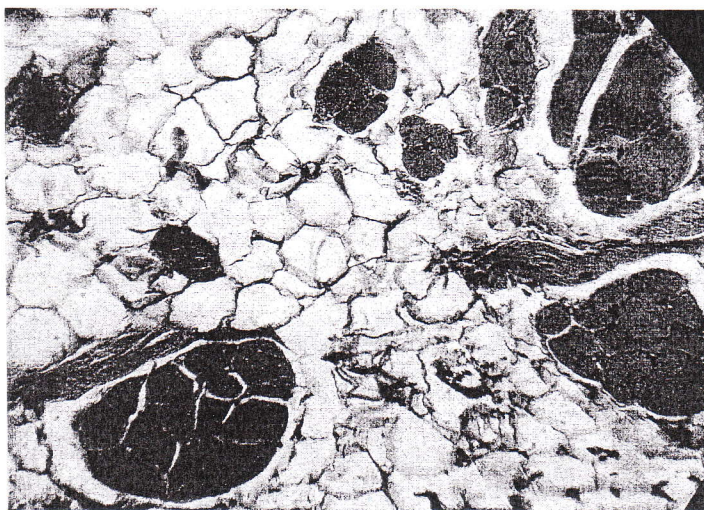
Results of control and experimental groups were analyzed statistically using T-test. These statistical tests were prepared using statistica program under Microsoft Excel XP

#### **Results**

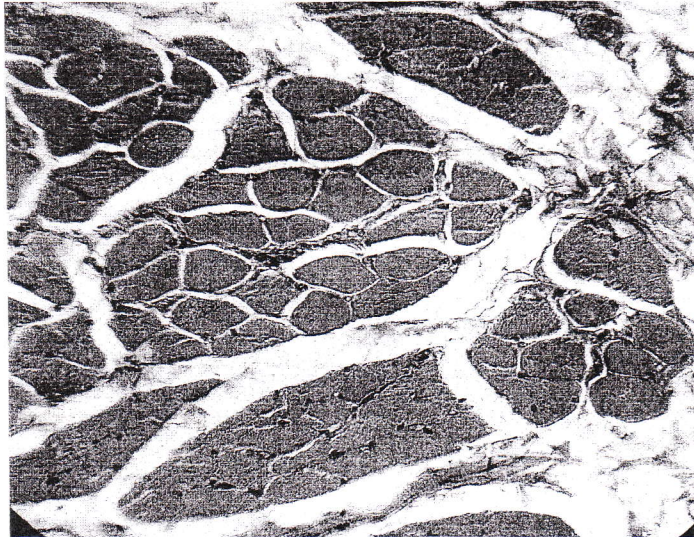
Muscle atrophy appeared clearly with increase in the thickness of perimysium and diffuse of adipose tissue fig.(1,2). At the fracture site there was a large area of cartilage and

fibrous tissue fig.(3). After 6 months, the mean length of biceps femoris muscle was  $8.43 \pm 1.22$ mm for the right side and  $8.46 \pm 1.91$ mm for the left, while the mean length of the rectus femoris muscle was  $5.35 \pm 1.05$ mm for the right side and  $6.37 \pm 0.93$ mm in the left side, in tibialis muscle the mean was  $5.20 \pm 1.18$ mm for the right side and  $5.13 \pm 0.89$ mm for the left side, while in soleus the mean was  $5.30 \pm 1.39$ mm for the right side and  $5.42 \pm 1.21$ mm for the left side. Statistically there was no significant shortening in the length of the right side compared with the left side in all muscles except in rectus femoris muscle.[table (1)]. The mean weight of biceps femoris muscle was  $7.39 \pm 2.00$ gm for the right side and  $9.99 \pm 1.75$ gm for left, while the mean length of the rectus femoris muscle was  $5.35 \pm 1.05$ gm for the right side and  $3.64 \pm 0.44$ gm in the left side, in tibialis muscle the mean was  $1.14 \pm 0.32$ gm for the right side and  $2.21$

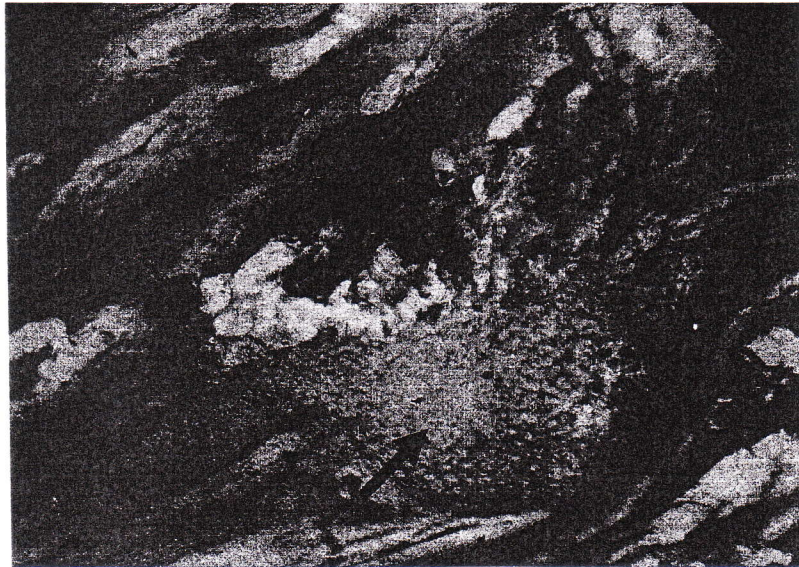
$\pm 0.62$ gm for the left side, while in soleus the mean was  $1.67 \pm 0.43$ gm for the right side and  $5.42 \pm 1.21$ gm for the left side. Statistically there was a significant decrease in the weight of the right side compared with the left side in all muscles.[table (2)]. The mean diameter of biceps femoris muscle fiber was  $27.90 \pm 0.87$  $\mu$ m for the right side and  $33.95 \pm 0.79$  $\mu$ m for left, while the mean length of the rectus femoris muscle was  $29.69 \pm 0.72$  $\mu$ m for the right side and  $33.08 \pm 0.84$  $\mu$ m in the left side, in tibialis muscle the mean was  $24.98 \pm 1.05$  $\mu$ m for the right side and  $32.78 \pm 0.77$  $\mu$ m for the left side, while in soleus the mean was  $25.48 \pm 0.96$  $\mu$ m for the right side and  $32.66 \pm 0.73$  $\mu$ m for the left side. Statistically there was a significant decrease in the diameter of muscle fiber of the right side compared with the left side in all muscles.[table (3)]



Figure(1):- muscle fibers atrophy and large area of adipose tissue,H&E ,10X.



**Figure(2):- increase in the thickness of perimysium connective tissue with diffuse muscle fibers atrophy, H&E 10X.**



**Figure(3):large area of cartilage (arrow) and fibrous tissue (arrow head) inside compact bone.H&E,40X.**

**Table (1):- Mean and Standard deviations of length of experimental and control muscles group.**

Muscle type	Muscle length right side(mm)(experimental)	Muscle length left side(mm)(control)
Biceps femoris	8.43 ±1.22	8.46 ±1.91
Rectus femoris	5.35 ±1.05*	6.37 ±0.93
Tibialis anterior	5.20 ±1.18	5.13 ±0.89
Soleus	5.30 ±1.39	5.42 ±1.21

**Table (2): Mean and Standard deviations of weight of experimental and control muscles group.**

Muscle type	Muscle weight right side(gm)(experimental)	Muscle weight left side(gm)(control)
Biceps femoris	7.39 ±2.00*	9.99 ±1.75
Rectus femoris	2.22 ±0.57*	3.64 ±0.44
Tibialis anterior	1.14 ±0.32*	2.21 ±0.62
Soleus	1.67 ±0.43*	2.39 ±0.61

**Table (3):- Mean and Standard deviations of experimental and control muscle fiber diameter.**

Muscle type	Muscle fiber diameter right side (µm) (experimental)	Muscle fiber diameter left side (µm) (control)
Biceps femoris	27.90 ±0.87*	33.95±0.79
Rectus femoris	29.69 ±0.72*	33.08 ±0.84
Tibialis anterior	24.98 ±1.05*	32.78 ±0.77
Soleus	25.48 ±0.96*	32.66 ±0.73

## **Discussion**

The aim of the present study was to demonstrate the effect of delay union in femoral bone fracture on the adjacent muscles. One definition of fracture is that, it is a severe soft tissue injury with an underlying bony defect. This definition is somewhat unusual in its emphasis on the soft tissue rather than bone involved in the condition, but it is a particularly useful definition for health professionals whose job is to get client back to full function within a reasonable period of time(26). Using a wire saw technique and intramedullary fixation for experimental bone fracture induction under a septic condition, was similar to that of Eesa(22) . this technique was used to minimize the complication that may occurred during experimental manual fracture(muscle tearing skin penetration, nerve injury, large blood vessels rupture and bleeding) to study the effect of delay union of fractured bone itself in specific condition from its complication. Results of the present investigation clarify that delay union in fractured bone was occurred due to the presence of gap between the 2 ends of fractured bone. This result is similar to that of (27)and(28) which found that increasing the gap width lead to delay in bone union in rat femur bone fracture ends, if the gap was 3mm or more lead to failure in bone union and formation of pseudoarthrosis in this study the degree of bone healing after 5 month was grade 3 as allen et al (29)classification it mean there is no complete bone union (delay union) because the normal or complete bone union in rabbit occurred after two month as revealed by Seddeek B.I. (5) There is no significant effect in length of muscle except in Rectus femoris but there were a significant effect(decrease)on weight and diameter in all adjacent muscles. It mean the atrophy which was normally occurred

in muscle due to fracture (30)continue after 5 month. This may be explained as nociceptive atrophy which is known to cause atrophy of the adjacent muscle and faraway muscles as reported by Urbancova h (31). When there was a delay union the bone cannot withstand the weight so their will be a pain in the area prevent the animals to use their lower limbs normally. And it was known that exercise and physical training increase sectional area of muscle fiber and the muscle bulk and strength and the immobilization or prolonged (12)rest produces profound change(atrophy) in muscle, particularly in lower limb (32,33)this is primarily because of a lack of weight bearing activity on muscles(34).

## **Reference**

- 1-Hirsch C.S.,Zumwalt R.E., In:Kissane J.M., Andersons pathology, Vol.1,9<sup>th</sup> Ed.,C.V.Mosby Company, 1990:114-115.
- 2-Sheldon S.,impaired bone healing in patients with diabetes mellitus, UMDNJ.edu. Vol.5, 2004,http:www.umdj.edu/research.
- 3-Garcia P.,Holstein j.,Development of a reliable Non- union Model in mice., J.surg.res., vol :147, Issue 1, 2003, pag:84-91.
- 4-Zacharova G., Urbancova H.K.,Hnik P., andSouskurp T., nociceptive atrophy of rat soleus muscle induced by bone fracture, J. App.physiol., vol.82, 1997:552-557.
- 5-seddeek B.I.,Experimental induction of femur bone fracture and its effect on theadjacent muscles and nerves in rabbit, 2006,Ms C. thesis submitted to college of medicine/university of tikrit.
- 6-Weaver A.H., anatomy &physiology,2<sup>nd</sup> Ed., Lippincott William &Wilkins, 2004:103-137.
- 7-Koivukangas A., Effect of long term clodronate administration on bone andon fracture healing in rat, Pharm. Res., Vol.(13),2002:304-337.

- 8-Dunning D., Basic mammalian bone anatomy and healing, *vet.cln-north-Am-Exot-Anim-prac.*, 2002,5(1):28-115.
- 9-Einhorn T.A., the cell and molecular biology of fracture healing, *Clin. Orthop.*, 1998:7-21.
- 10-Newton C.D., primery fracture healing, In: newton C.D., andnunamaker D.M., text book of small animal orthopedics, international veterinary information, 1985:121-185.
- 11-Greenbaum M.A., & Kanat I.O., Current concepts in to the bone healing, *JAM podiatry Med Assoc.*, Vol.83, 1993:123-129.
- 12-Jagmin M.G., Structure and function of musculoskeletal system, In: Copstead L.A., Banasik J.L., pathophysiology biological and behavioral perspectives, 2<sup>nd</sup> Ed, Saunder Company, 2000: 1127-1143.
- 13-Cruess R.L. & Dumont J., Conditions influencing fracture healing, In: Newton C.D. and Nunamaker D.M., Text book of small animal orthopedic, International veterinary information, 1985:186-221.
- 14-Claesl.,Auget P., suger G.,Influnce of the size and stability of the osteotomy gap on the success of fracture healing.,*J.Orthop. Res.*,15(4),1997: 84-577.
- 15-Quartro R., Thomas D., Liang C.T., Bone progenitor cell deficits and the age associated decline in bone repair capacity, *Calcif. Tissue.Int.*, 56(2),1995:9-123.
- 16-Vedi S.,Compston J.E.,Webb A., Histomorphometric analysis of bone biopsies from the iliac crest of normal British subject, *metab. bone.dis.relat.res.*,4(4),1982:6-231.
- 17-Funk J., Hale J., Carmines D., Biomechanical evaluation of fracture healing in normal and diabetic rats American society of biomechanics, Vol.10, 1997:34-72.
- 18-Brumbaugh P.F.,Speer D.P.,pitt M.J., 1-alpha, 25-Dihydroxy vitamin D3 a metabolite of vitamin D that promotes bone repair, *American Journal of pathology*, Vol.106,by American society for investigative pathology,1982:171-179.
- 19-Durak K., Sonmez G., Sarisozen B., Ozkan S., Kaya M., Histological assessment of the effect of vitamin E on fracture healing in rabbits, *J.int.Med.Res.*,31(1),2003 Jan-Fab.:26-30.
- 20-Heinonen A., Mckay H.A., Whittall K.P.,Muscle cross-sectional area is associated with specific site of bone in propuperta girls, quantitative magnetic resonance imaging study, *Bone*, Vol.29(4),2001 oct:92-388.
- 21-Petroianu A.,Corsetti R.A., Alberti L.R., The effect of presence muscle tissue in a bone healing site, *Rev.Hosp. clin.vol.59,no.4,4004:74-101.*
- 22-Eesa M.J., radiological and histological study on effect of the periosteum and endoseum on fracture healing, 1989, MsC.thesis submitted to the college of veterinary medicine/university of Babhdad.(in Arabic)
- 23-Al-Mudeffer, E.A.,A comparative study for application of fenestrated and non fenestrated bony tubular splints to diaphyseal femoral fractures in rabbits, 2000, Ms.C. thesis submitted to the college of veterinary Medicine/ university of Baghdad.(in Arabic)
- 24-Stephen D.,Loannis V.,Daniel S., effects of intermittent ischemia on contractile properteies and myosin isoform of skeletal muscle,*Official Journal of the American college of sports madicin*, Vol.30, Lippincott Williams & Wilkins, 1998:67.
- 25-Zacharova G., Urbancova H.K.,Hnik P.,and Souskurp T., Nociceptive atrophy of rat soleus muscle induced by bone fracture, *J. Appl.Physiol.*,vol.,82,1997:552-5570.
- 26-Gradisar I.A., Fracture stabilization and healing, In:orthopedic and sports physical therapy, Gould J.A., Davies



- G.J.,1985,by the C.V. Mosby company:118.
- 27-Resnick B., Henz R., normal and altered functions of the musculoskeletal system, In: Bullock B.A., Henz R.L., Focus on pathophysiology, lippincott William & Wilkins,2000,pag:793-879.
- 28-Lo-NN N.R.,Song I.C.,Effect of growth hormone on bone marrow grafts in fracture healing-an experimental study in rabbits, Ann.Acad.Med.singapore,Vol.24(3),1995:6-343.
- 29-Allen H.L.,Wase A.,Bear W.T.,Indomethacin and aspirin, effect of non steroidal anti-inflammatory agents on the rate of fracture rapair in rat, Acta. Orthop.Scand.,Vol.51,1980: 595-600.
- 30-Kubaa A.A-R., Athletic medicine, 1989, B00ks house for publishing, Ibn-Alatheer.st Mousl-Iraq, pag:6(in Arabic).
- 31-Urbancova h., Hnik P., Vejsada R., Bone fracture induces reflex muscle atrophy which is sex-dependent, Physiol-Res., Vol.42(1),1993:35-40.
- 32-Blomifield S.A.,Change in musculoskeletal structure and function with prolonged bed rest, Med.sci.spor. exc., Vol.29(2),1997:197-206.
- 33-Hudson N.J.,and Franklin C.E.,Maintaining muscle mass during extended disuse, the J.exp. boil., Vol.205,2002,The company of biologists limited:2297-2303.
- 34-Pierre B.A.,Flaskerud J.H.,Clinical nursing implications for the recovery of atrophic skeletal muscle following bed rest, Rehabilitation nursing, Vol.20(6),1995:7-314.